

# Circulation

JOURNAL OF THE AMERICAN HEART ASSOCIATION



## Acute Pulmonary Embolism: Part II: Treatment and Prophylaxis

Gregory Piazza and Samuel Z. Goldhaber

*Circulation* 2006;114:e42-e47

DOI: 10.1161/CIRCULATIONAHA.106.620880

Circulation is published by the American Heart Association, 7272 Greenville Avenue, Dallas, TX 75214

Copyright © 2006 American Heart Association. All rights reserved. Print ISSN: 0009-7322. Online ISSN: 1524-4539

The online version of this article, along with updated information and services, is located on the World Wide Web at:

<http://circ.ahajournals.org/cgi/content/full/114/3/e42>

Subscriptions: Information about subscribing to *Circulation* is online at  
<http://circ.ahajournals.org/subscriptions/>

Permissions: Permissions & Rights Desk, Lippincott Williams & Wilkins, a division of Wolters Kluwer Health, 351 West Camden Street, Baltimore, MD 21202-2436. Phone: 410-528-4050. Fax: 410-528-8550. E-mail:  
[journalpermissions@lww.com](mailto:journalpermissions@lww.com)

Reprints: Information about reprints can be found online at  
<http://www.lww.com/reprints>

## Acute Pulmonary Embolism Part II: Treatment and Prophylaxis

Gregory Piazza, MD; Samuel Z. Goldhaber, MD

**C**ase presentation: A 66-year-old man with a history of deep venous thrombosis (DVT) presented with acute dyspnea. He was normotensive, with a resting tachycardia of 110 beats per minute and an oxygen saturation of 76% on room air. The only electrocardiographic abnormality was sinus tachycardia. His brain-type natriuretic peptide (BNP) and cardiac troponin levels were elevated. Chest computed tomography (CT) with contrast demonstrated a large saddle pulmonary embolus and increased diameter of the right ventricle (RV) compared with the left ventricle (LV). The patient received intravenous bolus followed by continuous infusion unfractionated heparin. Within several hours, the patient became progressively more hypotensive and hypoxemic. Bedside transthoracic echocardiography (TTE) showed RV dilatation and hypokinesis. He then received intravenous fibrinolysis, with rapid improvement in hemodynamics and oxygenation. What were the clues that he was likely to suffer from progressive hypotension and hypoxemia?

### Risk Stratification

Pulmonary embolism (PE) represents a spectrum of syndromes ranging from

small peripheral emboli causing pleuritic pain to massive PE resulting in cardiogenic shock or cardiac arrest. Most patients with PE present with normal blood pressure. However, some may rapidly deteriorate and manifest systemic hypotension, cardiogenic shock, and sudden death despite therapeutic levels of anticoagulation. Risk stratification to identify such patients has emerged as a critical component of care.

The history and physical examination provide the starting point for risk stratification. The International Cooperative Pulmonary Embolism Registry (ICOPER) identified age >70 years, cancer, congestive heart failure, chronic obstructive pulmonary disease, and systolic blood pressure less than 90 mm Hg as significant predictors of increased mortality.<sup>1</sup>

Elevated cardiac biomarkers correlate with the presence of RV dysfunction, a powerful independent predictor of early mortality.<sup>2</sup> Whereas cardiac troponins are released as a result of microinfarction due to RV pressure overload, BNP is secreted from cardiac myocytes in response to RV shear stress.<sup>3</sup> Patients with PE and elevated cardiac biomarkers should undergo

TTE to test for the presence of RV dysfunction.<sup>3</sup>

Echocardiography is the imaging test of choice for risk stratification of patients with PE. Although normotensive patients with PE and no evidence of RV dysfunction generally have a benign hospital course, patients with RV dysfunction on echocardiography have an increased risk of hypotension, cardiogenic shock, and early death.<sup>2,4</sup>

RV enlargement as detected by chest CT has also been evaluated in the risk stratification of patients with acute-onset PE.<sup>5</sup> Using measurements from a reconstructed CT 4-chamber view, RV enlargement, defined as a ratio of RV to LV dimension of greater than 0.9, was a significant independent predictor of 30-day mortality.<sup>5</sup> An algorithm that synthesizes clinical indicators, cardiac biomarkers, and echocardiography or RV size on CT helps detect those patients with an increased risk of adverse events (Figure 1).

### Management

#### Spectrum of Disease

Patients with acute PE presenting with a normal blood pressure and no evidence of RV dysfunction generally

From the Division of Cardiology, Department of Medicine, Beth Israel Deaconess Medical Center (G.P.), and the Cardiovascular Division, Department of Medicine, Brigham and Women's Hospital (S.Z.G.), Harvard Medical School, Boston, Mass.

This article is Part II of a 2-part article. Part I appeared in the July 11, 2006, issue (*Circulation*. 2206;114:e28–e32).

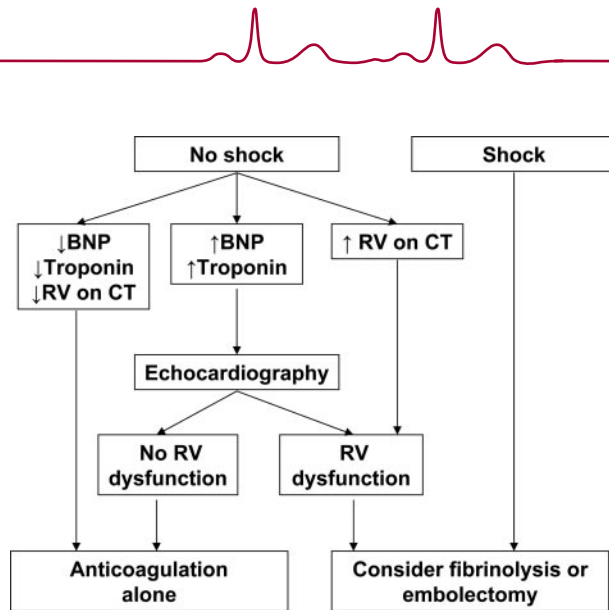
Correspondence to Samuel Z. Goldhaber, MD, Cardiovascular Division, Brigham and Women's Hospital, 75 Francis St, Boston, MA 02115. E-mail [sgoldhaber@partners.org](mailto:sgoldhaber@partners.org)

(*Circulation*. 2006;114:e42–e47.)

© 2006 American Heart Association, Inc.

*Circulation* is available at <http://www.circulationaha.org>

DOI: 10.1161/CIRCULATIONAHA.106.620880



**Figure 1.** An integrated approach to the risk stratification of patients with acute pulmonary embolism.

have a stable hospital course when treated with anticoagulation alone. Normotensive patients with PE and evidence of RV dysfunction are classified as having submassive PE and represent a population at elevated risk for adverse events and early mortality. Finally, massive PE describes patients presenting in cardiogenic shock.

### Primary Therapy

Primary therapy with fibrinolysis or embolectomy is generally considered for patients presenting with either massive or submassive PE. However, because of a relative paucity of randomized controlled trials, the use of primary therapy in the treatment of massive and submassive PE remains controversial.

The Food and Drug Administration (FDA) has approved t-PA (alteplase) 100 mg administered as a continuous infusion over 2 hours for the fibrinolysis of massive PE. Every patient being considered for fibrinolysis requires meticulous screening for contraindications because the bleeding risk may be as high as 3.0% for intracranial hemorrhage.<sup>1,6</sup> Although fibrinolysis is generally considered to be a lifesaving intervention in patients with massive PE, the extent of the clinical benefit remains unclear.<sup>7</sup> In a recent analysis of the ICOPER data, fibrinolytics did not reduce the rate of mortality or

recurrent PE at 90 days.<sup>7</sup> In submassive PE, the Management Strategies and Prognosis of Pulmonary Embolism-3 Trial (MAPPET-3) demonstrated a reduction in the need for escalation of therapy among patients receiving alteplase.<sup>8</sup>

In patients with massive or submassive PE in whom fibrinolysis is contraindicated or has failed, surgical embolectomy may be considered. Additional indications include paradoxical embolism, persistent right heart thrombi, and hemodynamic or respiratory compromise requiring cardiopulmonary resuscitation. In specialized centers caring for patients with massive PE, surgical embolectomy has been demonstrated to be a safe and effective treatment technique.<sup>9,10</sup>

Catheter-based pulmonary embolectomy is an emerging modality for the primary therapy of acute PE.<sup>11</sup> Catheter-based strategies are considered when fibrinolysis and open surgical embolectomy are contraindicated. In general, catheter-based embolectomy is most successful when applied to fresh thrombus within the first 5 days of symptoms of PE.


### Anticoagulation

Whether or not patients undergo primary therapy, anticoagulation is a critical component of the management of PE. The majority will receive intrave-

nous unfractionated heparin administered as a bolus followed by continuous infusion titrated to a target activated partial thromboplastin time of 2 to 3 times the upper limit of normal (approximately 60 to 80 seconds). Weight-based nomograms may achieve therapeutic levels of anticoagulation more quickly. Unfractionated heparin, which can be rapidly reversed, is preferred in patients undergoing fibrinolysis or embolectomy. In contrast to fibrinolysis in myocardial infarction, heparin is withheld during the administration of t-PA for PE and is not restarted until the activated partial thromboplastin time has fallen to less than twice the upper limit of normal.

Low-molecular-weight heparins (LMWHs) such as enoxaparin have been shown to be as safe and effective as intravenous unfractionated heparin.<sup>12,13</sup> LMWH monotherapy without oral anticoagulation appears promising and may be preferable in patients with malignancy.<sup>14–16</sup> LMWHs offer several advantages over unfractionated heparin including a longer half-life, increased bioavailability, and a more predictable dose response. In addition, LMWHs are dosed by weight, administered subcutaneously, and usually do not require dose adjustments or laboratory monitoring. Whereas unfractionated heparin is largely hepatically cleared, LMWHs are renally cleared. Patients with chronic kidney disease, massive obesity, pregnancy, or unanticipated bleeding or thromboembolism despite correct weight-based dosing of LMWH may benefit from laboratory monitoring. However, the utility of anti-Xa testing continues to be the subject of debate because the correlation of anti-Xa levels to anti-thrombotic effect and risk of bleeding has been questioned.<sup>17,18</sup>

Although the risk is lower with LMWH, use of both unfractionated heparin and LMWH is associated with the development of heparin-induced thrombocytopenia (HIT). HIT results from heparin-dependent immunoglobulin G antibodies directed against



**Figure 2.** An approach to therapy for acute pulmonary embolism.

heparin-platelet factor 4 complex and may lead to devastating arterial and venous thromboembolism. Whereas a benign transient decrease in platelets may be seen within the first few days of heparin administration, a decrease in platelet count of greater than 50% of baseline or a new thromboembolic event in the setting of any heparin product including heparin flushes should raise concern about possible HIT and lead to discontinuation of all heparin. Although it typically occurs within 4 to 14 days of heparin exposure, HIT may occur earlier if the patient has been previously exposed to heparin. Delayed-onset HIT should be considered in patients recently exposed to heparin who present with thromboembolism and experience thrombocytopenia on re-exposure.<sup>19</sup> If HIT is suspected or confirmed, clinicians should administer a direct thrombin inhibitor such as argatroban or lepirudin.

Fondaparinux is a synthetic pentasaccharide with anti-Xa activity approved by the FDA for the initial treatment of venous thromboembolism including PE. In hemodynamically stable patients with acute symptomatic PE, fondaparinux is as safe and effective as intravenous unfractionated hep-

arin.<sup>20</sup> Fondaparinux is administered subcutaneously on a once-daily basis in fixed doses of 5 mg for body weight <50 kg, 7.5 mg for body weight of 50 to 100 kg, and 10 mg for body weight >100 kg. Unlike intravenous unfractionated heparin, fondaparinux is administered in a fixed dose and does not require dose adjustment with laboratory coagulation tests. Fondaparinux, cleared through the renal route, is contraindicated in patients with severe renal disease. In contrast to heparin compounds, fondaparinux does not cause HIT.

Oral vitamin K antagonists such as warfarin have remained the mainstay of outpatient anticoagulation for venous thromboembolism (VTE). Oral anticoagulation is usually initiated simultaneously with heparin, LMWH, or fondaparinux and overlapped for at least 5 days until full therapeutic efficacy has been achieved. The target international normalized ratio (INR) is between 2.0 and 3.0 for the majority of patients with PE. Oral anticoagulation with warfarin must take into account the many drug-food, drug-alcohol, and drug-drug interactions. Genetic variation in warfarin metabolism leading to very slow metabolism of the

drug and lower maintenance doses presents an additional challenge.<sup>21,22</sup>

The effect of polymorphisms in the gene encoding vitamin K epoxide reductase complex 1 (*VKORC1*) on the response to warfarin was evaluated.<sup>23</sup> Ten common noncoding *VKORC1* single-nucleotide polymorphisms and 5 major haplotypes were identified.<sup>23</sup> The 5 major haplotypes were categorized into either a low-dose haplotype group (A) or a high-dose haplotype group (B).<sup>23</sup> The maintenance dose of warfarin differed significantly among the 3 combinations of these 2 haplotype groups, low-dose (A/A), intermediate-dose (A/B), and high-dose (B/B).<sup>23</sup> Of note, Asian-Americans demonstrated a higher proportion of group A haplotypes, whereas blacks had a higher proportion of group B haplotypes.<sup>23</sup> On the basis of these data, *VKORC1* haplotypes may explain differences in maintenance dose requirements among various patient populations and may permit stratification of patients into low-, intermediate-, or high-dose warfarin groups.<sup>23</sup>

The optimal duration of anticoagulation depends on the risk of recurrent VTE. In patients without reversible causes for DVT or PE, VTE represents a chronic illness with a high risk of recurrence after completion of standard anticoagulation. Several studies have evaluated the efficacy of indefinite anticoagulation for patients with idiopathic VTE.<sup>24-26</sup> A therapeutic algorithm that considers indefinite anticoagulation for patients with idiopathic VTE is critical (Figure 2).<sup>27</sup>

### Inferior Vena Cava Filters

Inferior vena cava (IVC) filters are indicated for patients in whom anticoagulation is contraindicated, those who experience recurrent PE despite adequate anticoagulation, and those undergoing open surgical embolectomy. IVC filters are associated with an increased incidence of DVT.<sup>28</sup> Although further studies are required, a recent analysis from ICOPER demonstrated a significant reduction in 90-day mortality associated with IVC filters.<sup>7</sup> Con-

**Regimens for Venous Thromboembolism Prophylaxis**

Condition	Prophylaxis
General surgery	Unfractionated heparin 5000 units SC TID <b>or</b> Enoxaparin 40 mg SC QD <b>or</b> Dalteparin 2500 or 5000 units SC QD
Orthopedic surgery	Warfarin (target INR 2.0 to 3.0) <b>or</b> Enoxaparin 30 mg SC BID <b>or</b> Enoxaparin 40 mg SC QD <b>or</b> Dalteparin 2500 or 5000 units SC QD <b>or</b> Fondaparinux 2.5 mg SC QD
Neurosurgery	Unfractionated heparin 5000 units SC BID <b>or</b> Enoxaparin 40 mg SC QD <b>and</b> Graduated compression stockings/intermittent pneumatic compression. Consider surveillance lower extremity ultrasonography.
Oncologic surgery	Enoxaparin 40 mg SC QD
Thoracic surgery	Unfractionated heparin 5000 units SC TID <b>and</b> Graduated compression stockings/intermittent pneumatic compression.
Medical patients	Unfractionated heparin 5000 units SC TID <b>or</b> Enoxaparin 40 mg SC QD <b>or</b> Dalteparin 5000 units SC QD <b>or</b> Fondaparinux 2.5 mg SC QD (not FDA approved) <b>or</b> Graduated compression stockings/intermittent pneumatic compression for patients with contraindications to anticoagulation. Consider combination pharmacological and mechanical prophylaxis for very high risk patients. Consider surveillance lower extremity ultrasonography for intensive care unit patients.

SC indicates subcutaneous; TID, 3 times daily; QD, daily; and BID, twice daily.

sider using retrievable IVC filters for patients with transient contraindications to anticoagulation.<sup>29</sup>

**Prevention**

Although mechanical and pharmacological VTE prophylaxis should be nearly universal among hospitalized patients, implementation of prophylaxis continues to be inconsistent. A computer-alert program at Brigham and Women's Hospital increased physician utilization of VTE prophylaxis and resulted in a 41% risk reduction in the frequency of symptomatic DVT or PE.<sup>30</sup>

The risk of VTE persists after hospital discharge especially among postoperative patients. Several studies have validated the use of extended VTE prophylaxis for 4 to 6 weeks in patients undergoing oncological or orthopedic surgery.<sup>31–33</sup>

Prophylactic regimens use mechanical and pharmacological modalities (Table).<sup>34</sup> Mechanical prophylactic devices including graduated compression stockings and intermittent pneumatic compression increase venous blood flow and may enhance endogenous fibrinolysis, leading to reductions in VTE.<sup>35</sup> Agents for pharmacological prophylaxis include subcutaneously administered unfractionated heparin, LMWH, warfarin, and fondaparinux. Certain high-risk populations such as neurosurgical patients may benefit from a combination of mechanical and pharmacological prophylaxis.

The DVT Free Registry demonstrated that VTE prophylaxis continues to be underutilized in hospitalized patients on Medical Services.<sup>36</sup> Several studies have evaluated the safety and efficacy of various VTE prophylactic regimens in medical pa-

tients. Daily subcutaneously administered enoxaparin has been shown to safely reduce the risk of VTE among patients admitted with acute medical illnesses.<sup>37</sup> In a large, randomized, placebo-controlled trial of acutely ill medical patients, the LMWH dalteparin (5000 IU subcutaneously once daily) halved the rate of VTE, with a low risk of bleeding.<sup>38</sup> The Arixtra for Thromboembolism Prevention in a Medical Indications Study (ARTEMIS) found that fondaparinux (2.5 mg subcutaneously once daily) reduced the risk of VTE among medical patients by 47%.<sup>39</sup>

Orthopedic patients demonstrate a significantly elevated risk of VTE even after discharge from the hospital. Several studies have validated extended out-of-hospital prophylaxis with warfarin or LMWH in the prevention of VTE among orthopedic patients.<sup>32,33,40</sup> Fondaparinux (2.5 mg subcutaneously once daily) safely and effectively reduces the risk of VTE in patients undergoing hip replacement, major knee surgery, and hip fracture repair.<sup>41–44</sup>

Abdominal or pelvic surgery for malignancy is associated with an elevated risk of postoperative VTE. The Enoxaparin and Cancer (ENOX-ACAN) II study demonstrated that extended-duration prophylaxis with enoxaparin reduced the risk of VTE in this patient population.<sup>31</sup>

**Case Presentation**

The case presented highlights the fact that a subset of initially normotensive PE patients will deteriorate and develop hemodynamic instability. The case also demonstrates that these high-risk patients may be identified by elevations in cardiac biomarkers including troponin as well as by echocardiographic and chest CT evidence of RV dysfunction. RV dysfunction is an important predictor of adverse events and should lead the clinician to consider the option of fibrinolysis or embolectomy in addition to anticoagulation.

**Sources of Funding**


Dr Goldhaber received research grants from Sanofi Aventis and GlaxoSmithKline.

## Disclosures

Dr Goldhaber has served as a consultant to or on an advisory board for Sanofi Aventis. Dr Piazza reports no conflicts.

## References

- Goldhaber SZ, Visani L, De Rosa M. Acute pulmonary embolism: clinical outcomes in the International Cooperative Pulmonary Embolism Registry (ICOPER). *Lancet*. 1999;353:1386–1389.
- Kucher N, Rossi E, De Rosa M, Goldhaber SZ. Prognostic role of echocardiography among patients with acute pulmonary embolism and a systolic arterial pressure of 90 mm Hg or higher. *Arch Intern Med*. 2005;165:1777–1781.
- Kucher N, Goldhaber SZ. Cardiac biomarkers for risk stratification of patients with acute pulmonary embolism. *Circulation*. 2003;108:2191–2194.
- Goldhaber SZ. Echocardiography in the management of pulmonary embolism. *Ann Intern Med*. 2002;136:691–700.
- Schoepf UJ, Kucher N, Kipfmüller F, Quiroz R, Costello P, Goldhaber SZ. Right ventricular enlargement on chest computed tomography: a predictor of early death in acute pulmonary embolism. *Circulation*. 2004;110:3276–3280.
- Thabut G, Thabut D, Myers RP, Bernard-Chabert B, Marrash-Chahla R, Mal H, Fournier M. Thrombolytic therapy of pulmonary embolism: a meta-analysis. *J Am Coll Cardiol*. 2002;40:1660–1667.
- Kucher N, Rossi E, De Rosa M, Goldhaber SZ. Massive pulmonary embolism. *Circulation*. 2006;113:577–582.
- Konstantinides S, Geibel A, Heusel G, Heinrich F, Kasper W. Heparin plus alteplase compared with heparin alone in patients with submassive pulmonary embolism. *N Engl J Med*. 2002;347:1143–1150.
- Leacche M, Unic D, Goldhaber SZ, Rawn JD, Aranki SF, Couper GS, Mihaljevic T, Rizzo RJ, Cohn LH, Aklog L, Byrne JG. Modern surgical treatment of massive pulmonary embolism: results in 47 consecutive patients after rapid diagnosis and aggressive surgical approach. *J Thorac Cardiovasc Surg*. 2005;129:1018–1023.
- Aklog L, Williams CS, Byrne JG, Goldhaber SZ. Acute pulmonary embolectomy: a contemporary approach. *Circulation*. 2002;105:1416–1419.
- Kucher N, Windecker S, Banz Y, Schmitz-Rode T, Mettler D, Meier B, Hess OM. Percutaneous catheter thrombectomy device for acute pulmonary embolism: in vitro and in vivo testing. *Radiology*. 2005;236:852–858.
- Simonneau G, Sors H, Charbonnier B, Page Y, Laaban JP, Azarian R, Laurent M, Hirsch JL, Ferrari E, Bosson JL, Mottier D, Beau B. A comparison of low-molecular-weight heparin with unfractionated heparin for acute pulmonary embolism. The THESEE Study Group Tinzaparine ou Heparine Standard: Evaluations dans l'Embolie Pulmonaire. *N Engl J Med*. 1997;337:663–669.
- Low-molecular-weight heparin in the treatment of patients with venous thromboembolism. The Columbus Investigators. *N Engl J Med*. 1997;337:657–662.
- Lee AY, Levine MN, Baker RI, Bowden C, Kakkar AK, Prins M, Rickles FR, Julian JA, Haley S, Kovacs MJ, Gent M. Low-molecular-weight heparin versus a coumarin for the prevention of recurrent venous thromboembolism in patients with cancer. *N Engl J Med*. 2003;349:146–153.
- Kucher N, Quiroz R, McKean S, Sasahara AA, Goldhaber SZ. Extended enoxaparin monotherapy for acute symptomatic pulmonary embolism. *Vasc Med*. 2005;10:251–256.
- Beckman JA, Dunn K, Sasahara AA, Goldhaber SZ. Enoxaparin monotherapy without oral anticoagulation to treat acute symptomatic pulmonary embolism. *Thromb Haemost*. 2003;89:953–958.
- Bounameaux H, de Moerloose P. Is laboratory monitoring of low-molecular-weight heparin therapy necessary? No. *J Thromb Haemost*. 2004;2:551–554.
- Harenberg J. Is laboratory monitoring of low-molecular-weight heparin therapy necessary? Yes. *J Thromb Haemost*. 2004;2:547–550.
- Rice L, Attisha WK, Drexler A, Francis JL. Delayed-onset heparin-induced thrombocytopenia. *Ann Intern Med*. 2002;136:210–215.
- Buller HR, Davidson BL, Decousus H, Gallus A, Gent M, Piovella F, Prins MH, Raskob G, van den Berg-Segers AE, Cariou R, Leeuwkamp O, Lensing AW. Subcutaneous fondaparinux versus intravenous unfractionated heparin in the initial treatment of pulmonary embolism. *N Engl J Med*. 2003;349:1695–1702.
- Higashi MK, Veenstra DL, Kondo LM, Wittkowsky AK, Srinouanprachanh SL, Farin FM, Rettie AE. Association between CYP2C9 genetic variants and anticoagulation-related outcomes during warfarin therapy. *JAMA*. 2002;287:1690–1698.
- Joffe HV, Xu R, Johnson FB, Longtine J, Kucher N, Goldhaber SZ. Warfarin dosing and cytochrome P450 2C9 polymorphisms. *Thromb Haemost*. 2004;91:1123–1128.
- Rieder MJ, Reiner AP, Gage BF, Nickerson DA, Eby CS, McLeod HL, Blough DK, Thummel KE, Veenstra DL, Rettie AE. Effect of VKORC1 haplotypes on transcriptional regulation and warfarin dose. *N Engl J Med*. 2005;352:2285–2293.
- Schulman S, Wahlander K, Lundstrom T, Clason SB, Eriksson H. Secondary prevention of venous thromboembolism with the oral direct thrombin inhibitor ximelagatran. *N Engl J Med*. 2003;349:1713–1721.
- Ridker PM, Goldhaber SZ, Danielson E, Rosenberg Y, Eby CS, Deitcher SR, Cushman M, Moll S, Kessler CM, Elliott CG, Paulson R, Wong T, Bauer KA, Schwartz BA, Miletich JP, Bounameaux H, Glynn RJ. Long-term, low-intensity warfarin therapy for the prevention of recurrent venous thromboembolism. *N Engl J Med*. 2003;348:1425–1434.
- Keaton C, Ginsberg JS, Kovacs MJ, Anderson DR, Wells P, Julian JA, MacKinnon B, Weitz JI, Crowther MA, Dolan S, Turpie AG, Geerts W, Solyomoss S, van Nguyen P, Demers C, Kahn SR, Kassis J, Rodger M, Hambleton J, Gent M. Comparison of low-intensity warfarin therapy with conventional-intensity warfarin therapy for long-term prevention of recurrent venous thromboembolism. *N Engl J Med*. 2003;349:631–639.
- Goldhaber SZ, Elliott CG. Acute pulmonary embolism: part II: risk stratification, treatment, and prevention. *Circulation*. 2003;108:2834–2838.
- Decousus H, Leizorovicz A, Parent F, Page Y, Tardy B, Girard P, Laporte S, Faivre R, Charbonnier B, Barral FG, Huet Y, Simonneau G. A clinical trial of vena caval filters in the prevention of pulmonary embolism in patients with proximal deep-vein thrombosis. Prevention du Risque d'Embolie Pulmonaire par Interruption Cave Study Group. *N Engl J Med*. 1998;338:409–415.
- Millward SF, Oliva VL, Bell SD, Valenti DA, Rasuli P, Asch M, Hadziomerovic A, Kachura JR. Gunther Tulip Retrievable Vena Cava Filter: results from the Registry of the Canadian Interventional Radiology Association. *J Vasc Interv Radiol*. 2001;12:1053–1058.
- Kucher N, Koo S, Quiroz R, Cooper JM, Paterno MD, Soukonnikov B, Goldhaber SZ. Electronic alerts to prevent venous thromboembolism among hospitalized patients. *N Engl J Med*. 2005;352:969–977.
- Bergqvist D, Agnelli G, Cohen AT, Eldor A, Nilsson PE, Le Moigne-Amrani A, Dietrich-Neto F. Duration of prophylaxis against venous thromboembolism with enoxaparin after surgery for cancer. *N Engl J Med*. 2002;346:975–980.
- Eikelboom JW, Quinlan DJ, Douketis JD. Extended-duration prophylaxis against venous thromboembolism after total hip or knee replacement: a meta-analysis of the randomised trials. *Lancet*. 2001;358:9–15.
- Hull RD, Pineo GF, Stein PD, Mah AF, MacIsaac SM, Dahl OE, Butcher M, Brant RF, Ghali WA, Bergqvist D, Raskob GE. Extended out-of-hospital low-molecular-weight heparin prophylaxis against deep venous thrombosis in patients after elective hip arthroplasty: a systematic review. *Ann Intern Med*. 2001;135:858–869.
- Goldhaber SZ. Pulmonary embolism. *Lancet*. 2004;363:1295–1305.
- Urbankova J, Quiroz R, Kucher N, Goldhaber SZ. Intermittent pneumatic compression and deep vein thrombosis prevention: a meta-analysis in postoperative patients. *Thromb Haemost*. 2005;94:1181–1185.
- Goldhaber SZ, Tapson VF. A prospective registry of 5,451 patients with ultrasound-confirmed deep vein thrombosis. *Am J Cardiol*. 2004;93:259–262.
- Samama MM, Cohen AT, Darmon JY, Desjardins L, Eldor A, Janbon C, Leizorovicz A, Nguyen H, Olsson CG, Turpie AG, Weisslinger N. A comparison

- 
- of enoxaparin with placebo for the prevention of venous thromboembolism in acutely ill medical patients. Prophylaxis in Medical Patients with Enoxaparin Study Group. *N Engl J Med.* 1999;341:793–800.
38. Leizorovicz A, Cohen AT, Turpie AG, Olsson CG, Vaitkus PT, Goldhaber SZ. Randomized, placebo-controlled trial of dalteparin for the prevention of venous thromboembolism in acutely ill medical patients. *Circulation.* 2004;110:874–879.
39. Cohen AT, Davidson BL, Gallus AS, Lassen MR, Prins MH, Tomkowski W, Turpie AG, Egberts JF, Lensing AW. Efficacy and safety of fondaparinux for the prevention of venous thromboembolism in older acute medical patients: randomised placebo controlled trial. *BMJ.* 2006;332:325–329.
40. White RH, Gettner S, Newman JM, Trauner KB, Romano PS. Predictors of rehospitalization for symptomatic venous thromboembolism after total hip arthroplasty. *N Engl J Med.* 2000;343:1758–1764.
41. Bauer KA, Eriksson BI, Lassen MR, Turpie AG. Fondaparinux compared with enoxaparin for the prevention of venous thromboembolism after elective major knee surgery. *N Engl J Med.* 2001;345:1305–1310.
42. Eriksson BI, Bauer KA, Lassen MR, Turpie AG. Fondaparinux compared with enoxaparin for the prevention of venous thromboembolism after hip-fracture surgery. *N Engl J Med.* 2001;345:1298–1304.
43. Turpie AG, Bauer KA, Eriksson BI, Lassen MR. Fondaparinux vs enoxaparin for the prevention of venous thromboembolism in major orthopedic surgery: a meta-analysis of 4 randomized double-blind studies. *Arch Intern Med.* 2002;162:1833–1840.
44. Turpie AG, Gallus AS, Hoek JA. A synthetic pentasaccharide for the prevention of deep-vein thrombosis after total hip replacement. *N Engl J Med.* 2001;344:619–625.