

ORIGINAL ARTICLE

## Effusive–Constrictive Pericarditis

Jaume Sagristà-Sauleda, M.D., Juan Angel, M.D., Antonio Sánchez, M.D.,  
Gaietà Permanyer-Miralda, M.D., and Jordi Soler-Soler, M.D.

### ABSTRACT

#### BACKGROUND

Effusive–constrictive pericarditis is an uncommon pericardial syndrome characterized by concomitant tamponade, caused by tense pericardial effusion, and constriction, caused by the visceral pericardium. We conducted a prospective study of its clinical evolution and management.

#### METHODS

From 1986 through 2001, all patients with effusive–constrictive pericarditis were prospectively evaluated. Combined pericardiocentesis and cardiac catheterization were performed in all patients, and pericardiectomy was performed in those with persistent constriction. Follow-up ranged from 1 month to 15 years (median, 7 years).

#### RESULTS

A total of 1184 patients with pericarditis were evaluated, 218 of whom had tamponade. Of these 218, 190 underwent combined pericardiocentesis and catheterization. Fifteen of these patients had effusive–constrictive pericarditis and were included in the study. All patients presented with clinical tamponade; however, concomitant constriction was recognized in only seven patients. At catheterization, all patients had elevated intrapericardial pressure (median, 12 mm Hg; interquartile range, 7 to 18) and elevated right atrial and end-diastolic right and left ventricular pressures. After pericardiocentesis, the intrapericardial pressure decreased (median value, –5 mm Hg; interquartile range, –5 to 0), whereas right atrial and end-diastolic right and left ventricular pressures, although slightly reduced, remained elevated, with a dip–plateau morphology. The causes were diverse, and death was mainly related to the underlying disease. Pericardiectomy was required in seven patients, all of whom had involvement of the visceral pericardium. Three patients had spontaneous resolution.

#### CONCLUSIONS

Effusive–constrictive pericarditis is an uncommon pericardial syndrome that may be missed in some patients who present with tamponade. Although evolution to persistent constriction is frequent, idiopathic cases may resolve spontaneously. In our opinion, extensive epicardiectomy is the procedure of choice in patients requiring surgery.

From the Servei de Cardiologia, Hospital General Universitari Vall d'Hebron, Barcelona, Spain. Address reprint requests to Dr. Sagristà-Sauleda at the Servei de Cardiologia, Hospital General Universitari Vall d'Hebron, C/P. Vall d'Hebron 119-129, 08035 Barcelona, Spain.

N Engl J Med 2004;350:469-75.

Copyright © 2004 Massachusetts Medical Society.

**E**FFUSIVE-CONSTRICTIVE PERICARDITIS is a clinical hemodynamic syndrome in which constriction of the heart by the visceral pericardium occurs in the presence of tense effusion in a free pericardial space. This variety of constrictive pericarditis was observed many years ago by Burchell<sup>1</sup> and Spodick and Kumar<sup>2</sup> but was not well characterized until the report by Hancock<sup>3</sup> on 13 patients undergoing pericardiectomy, 11 of whom had previously undergone combined pericardiocentesis and cardiac catheterization.

The hallmark of effusive-constrictive pericarditis is the persistence of elevated right atrial pressure after intrapericardial pressure has been reduced to normal levels by removal of pericardial fluid. Apart from the two early Stanford University series,<sup>3,4</sup> only isolated case reports have been published. However, the Stanford series included only patients undergoing pericardiectomy; thus, it is probably not representative of the broad clinical spectrum of effusive-constrictive pericarditis. We studied 15 patients with effusive-constrictive pericarditis who were prospectively identified in a series of 190 consecutive patients with clinical tamponade who underwent pericardiocentesis and cardiac catheterization over a 16-year period; our goal was to ascertain the prevalence, clinical findings, hemodynamic aspects, and evolution of this poorly known pericardial syndrome.

---

## METHODS

---

### DEFINITIONS

The diagnosis of effusive-constrictive pericarditis was established on the basis of hemodynamic findings during combined pericardiocentesis and cardiac catheterization. The diagnostic criterion was tamponade that evolved into constriction (with failure of the right atrial pressure to fall by 50 percent or more or to a level below 10 mm Hg) after intrapericardial pressure was lowered to near 0 mm Hg by the removal of pericardial fluid.

### PATIENTS

This series includes all patients who received a diagnosis of effusive-constrictive pericarditis at our institution from 1986 through 2001. All patients were recruited from those in our hospital ward who had received a diagnosis of clinical tamponade requiring pericardiocentesis. Whenever possible, pericardiocentesis was performed in the catheterization laboratory. The clinical evaluation of each patient included a complete medical history taking, phys-

ical examination, electrocardiography, chest radiography, Doppler echocardiography, and pertinent laboratory tests.<sup>5,6</sup> Written informed consent for pericardiocentesis and cardiac catheterization was obtained from all patients. Since 1986, it has been our routine practice to perform pericardiocentesis in the catheterization laboratory, including measurement of intrapericardial pressure before and after pericardiocentesis.

Two 5-French pigtail angiographic catheters were used for pericardiocentesis and to record intrapericardial and left ventricular pressures simultaneously. Right atrial or right ventricular pressures were recorded with a multipurpose 5-French catheter. Hemodynamic pulsus paradoxus was measured from a recording of femoral-artery pressure obtained during spontaneous respiration. The average of the differences of all measurements of instantaneous right atrial and intrapericardial pressures during three spontaneous respiratory cycles (taken every 0.2 second during the second half of expiration) was considered the right atrial transmural pressure. Pressure measurements were repeated after the removal of pericardial fluid. We measured the levels of glucose, total protein, cholesterol, lactate dehydrogenase, and adenosine deaminase in pericardial fluid; performed cytologic studies and aerobic and anaerobic bacterial cultures of pericardial fluid; and determined whether acid-fast bacilli were present in pericardial fluid.

Medical treatment was based on the results of the etiologic investigation, with oral administration of nonsteroidal antiinflammatory drugs and appropriate treatment for specific conditions. The use of corticosteroids was avoided. Pericardiectomy was considered to be indicated in patients with evolution to constrictive pericarditis and clinical features of severe and persistent heart failure. In cases of mild or moderate heart failure, medical treatment was attempted so as to allow for the possible spontaneous clinical resolution.

### FOLLOW-UP

Patients were monitored in the outpatient clinic. After pericardiocentesis, they were seen every three months during the first year and yearly thereafter, or whenever symptoms developed. After pericardiectomy, they were seen every three to five years after the first year.

### STATISTICAL ANALYSIS

Data on catheterization are presented as medians with interquartile ranges. We compared values be-

fore and after pericardiocentesis using Wilcoxon's signed-rank test.

## RESULTS

### CLINICAL FINDINGS

Among 1184 consecutive patients with pericarditis of any type, 218 had clinical tamponade; of these, 190 underwent combined pericardiocentesis and cardiac catheterization with accurate measurement of intrapericardial pressure and right atrial and right and left ventricular pressures according to our protocol. Fifteen of these patients (3 women and 12 men; age range, 18 to 66 years; median age, 46 years) fulfilled our criteria for effusive-constrictive pericarditis. All patients had clinical manifestations of right heart failure with jugular venous distention and hepatomegaly. Arterial pulsus paradoxus (between 10 and 20 mm Hg) was present in 10 patients. Pericardial calcification was not apparent on radiographic examination in any patient.

The symptoms had begun between 4 days and 26 months before admission; 12 patients had had symptoms for less than 3 months; 2 patients with a history of chest radiation had had vague symptoms for the previous 24 and 26 months, respectively; and in 1 patient the precise duration of symptoms could not be established. Two of seven patients with a history of cancer had received chest radiation. Eight patients had clinical features of inflammation (pericardial chest pain, fever, and pericardial rub). All patients were in sinus rhythm. On chest radiography, the cardiothoracic index ranged from 0.54 to 0.74. Lung fields were clear in all patients. On echocardiography, the sum of anterior and posterior echo-free spaces at end diastole ranged from 20 to 34 mm. Right atrial or right ventricular collapse was found in eight patients.

Before pericardiocentesis, the diagnosis of effusive-constrictive pericarditis had been suspected in seven patients owing to the presence of abnormal septal motion and transmitral and transtricuspid Doppler recordings showing rapid forward flow in diastole and reverse flow in late systole, in addition to pericardial effusion with chamber collapse. The dimensions of the left and right atrial and ventricular chambers were normal in all patients. Pericardial fluid was serosanguineous in 14 patients and serofibrinous in 1. The protein concentration ranged from 2.7 to 7 g per liter (normal range, 1.7 to 3.5). Cultures for bacteria, fungi, and acid-fast bacilli were negative in all patients.

### FINDINGS AT CATHETERIZATION

Findings at pericardiocentesis and cardiac catheterization are shown in Table 1. Before pericardiocentesis, intrapericardial pressure (median, 12 mm Hg; interquartile range, 7 to 18), right atrial pressure (median, 17 mm Hg; interquartile range, 15 to 21), end-diastolic right ventricular pressure (median, 19 mm Hg; interquartile range, 17 to 22), and end-diastolic left ventricular pressure (median, 21.5 mm Hg; interquartile range, 20 to 22) were high. Cardiac output was reduced (median cardiac index, 2.1 liters per minute per square meter; interquartile range, 1.9 to 2.7), and the median arterial pulsus paradoxus was 15 mm Hg (interquartile range, 12 to 20). Right atrial transmural pressure was low (median, 1 mm Hg; interquartile range, 0 to 3).

After pericardiocentesis, intrapericardial pressure showed a marked decrease (median, -5 mm Hg; interquartile range, -5 to 0;  $P < 0.001$ ), as did pulsus paradoxus (median, 8 mm Hg; interquartile range, 8 to 10;  $P < 0.05$ ). Right atrial transmural pressure markedly increased (median, 12 mm Hg; interquartile range, 8 to 18;  $P < 0.001$ ). There also were small reductions in right atrial pressure (median, 15 mm Hg; interquartile range, 12 to 22) and end-diastolic right ventricular pressure (median, 17.5 mm Hg; interquartile range, 14 to 21;  $P < 0.05$ ), whereas the cardiac index increased slightly (median, 2.4 liters per minute per square meter; interquartile range, 2.0 to 2.9;  $P = 0.007$ ). End-diastolic left ventricular pressure (median, 20.5 mm Hg; interquartile range, 16 to 24) did not change significantly.

Before pericardiocentesis, right atrial pressure morphology (recorded in 11 patients) showed a pattern in which X exceeded Y in 6 patients, X equaled Y in 4, and X was less than Y in 1. After pericardiocentesis, right atrial pressure morphology (recorded in all 15 patients) showed a pattern in which X exceeded Y in 1 patient, X equaled Y in 8, and X was less than Y in 6. In all patients, diastolic ventricular pressure showed a dip-plateau morphology. A typical hemodynamic tracing is shown in Figure 1.

### THERAPEUTIC PROCEDURES

Patients with inflammatory symptoms were given oral nonsteroidal antiinflammatory drugs. Antituberculous chemotherapy was administered in one patient. None of the patients received corticosteroids. Uneventful pericardiocentesis was performed

**Table 1. Findings at Catheterization.\***

Patient No.	Before Pericardiocentesis									Volume Obtained by Pericardiocentesis ml	After Pericardiocentesis									
	CPP	HPP	Cardiac Index	IP	RA	RAM	RAT	RVD	LVD		HPP	Cardiac Index	IP	RA	RAM	RAT	RVD	LVD	Dip-Plateau Morphology	
	mm Hg			mm Hg			mm Hg				mm Hg		mm Hg							
1	No	10	ND	6	19	NA	4	19	21	500	10	ND	-5	18	X=Y	11	16	16	Yes	
2†		15	10	2.85	12	17	NA	1	19	20	450	10	4.26	1	14	X=Y	15	14	18	Yes
3		15	18	2.88	7	12	NA	1	12	12	600	8	3.64	-5	10	X<Y	12	9	10	Yes
4†	No	14	2.80	6	6	NA	0	ND	10	300	10	2.94	-5	7	X<Y	8	ND	14	Yes	
5		15	8	2.15	9	17	X>Y	3	17	22	700	7	2.22	-2	14	X=Y	9	14	22	Yes
6		20	12	2.16	14	17	X=Y	-1	19	21	500	8	2.42	0	15	X=Y	7	18	22	Yes
7	No	14	1.19	7	15	X>Y	8	18	22	250	11	1.21	-3	17	X<Y	18	19	24	Yes	
8		20	18	2.29	14	15	X>Y	0	ND	16	250	8	3.24	-5	12	X>Y	12	ND	15	Yes
9†	No	24	1.71	11	15	X=Y	0	17	22	500	8	2.00	3	16	X=Y	5	17	26	Yes	
10		10	30	1.64	18	18	X>Y	0	ND	21	1100	5	2.61	-5	11	X<Y	8	ND	26	Yes
11		10	20	2.74	10	15	X>Y	0	ND	22	600	15	2.50	-5	13	X<Y	18	ND	18	Yes
12	No	16	1.86	14	21	X>Y	3	22	23	210	8	1.92	-5	22	X=Y	20	21	21	Yes	
13		20	12	2.17	21	35	X=Y	3	ND	35	460	8	2.23	-5	26	X=Y	25	ND	26	Yes
14		20	ND	ND	25	30	X=Y	0	30	ND	1100	ND	ND	+8	23	X=Y	15	25	ND	Yes
15		15	20	1.95	23	27	X<Y	2	26	32	220	12	2.01	-2	27	X<Y	20	23	32	Yes

\* CPP denotes clinical pulsus paradoxus, HPP hemodynamic pulsus paradoxus (measured in the femoral artery), IP mean intrapericardial pressure, RA mean right atrial pressure, RAM right-atrial–pressure morphology, RAT right atrial transmural pressure, RVD right ventricular end-diastolic pressure, LVD left ventricular end-diastolic pressure, No not apparant, NA not available, and ND not done.

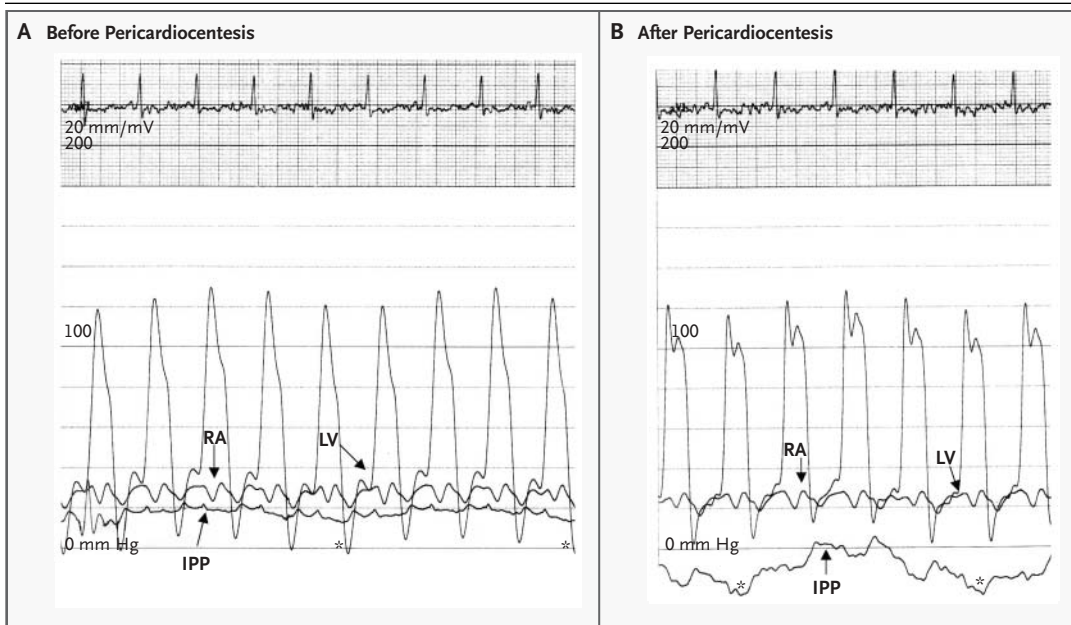
† Effusive–constrictive pericarditis spontaneously resolved.

in all 15 patients. The volume of pericardial fluid removed ranged from 210 to 1100 ml (median, 500; interquartile range, 250 to 610). After pericardiocentesis, clinical status failed to improve in two patients; eight patients had a mild improvement, and five patients had a marked improvement (one patient with lymphoma required additional chemotherapy and chest radiation, one patient was lost to follow-up after hospital discharge, and three patients had a complete resolution after a follow-up of 15 years, 13 years, and 3 years, respectively). Two patients with neoplastic pericarditis required a second pericardial-drainage procedure owing to the reaccumulation of pericardial fluid.

Wide anterior pericardiectomy was performed in seven patients between 13 days and 4 months after pericardiocentesis owing to the persistence of severe right heart failure. The diagnoses in these seven patients were idiopathic pericarditis in four, radiation pericarditis in one, tuberculous pericardi-

itis in one, and postsurgical pericarditis in one. Extensive thickening of both visceral pericardium (5 to 6 mm) and parietal pericardium (3 to 6 mm) with areas of adherence between them was found at surgery in each patient. Two patients had free pericardial fluid (150 and 250 ml, respectively). The surgical procedure consisted of wide removal of both the parietal pericardium and various amounts of the visceral pericardium. The visceral pericardiectomy proved difficult, requiring sharp dissection of many small fragments until an improvement in ventricular motion was observed. Histopathological examination of the resected pericardium showed fibrotic thickening and nonspecific inflammation. Two deaths occurred in the early postoperative period: one patient with postsurgical pericarditis died as a consequence of ischemic heart disease, and the other patient, who had idiopathic pericarditis, died of severe biventricular heart failure.

Pericardiectomy was not indicated in eight pa-



**Figure 1.** Findings at Catheterization during Two Spontaneous Respiratory Cycles in Patient 13 before and after Pericardiocentesis.

Before pericardiocentesis (Panel A), the intrapericardial pressure (IPP) is elevated (21 mm Hg), as are the right atrial (RA) pressure (35 mm Hg) and end-diastolic left ventricular (LV) pressure (35 mm Hg). After pericardiocentesis (Panel B), the intrapericardial pressure drops below 0 mm Hg, whereas the right atrial and left ventricular pressures are practically unchanged and a dip-plateau morphology of left intraventricular pressure is apparent. Asterisks indicate the end of the inspiratory phase.

tients: because of good clinical evolution and eventual spontaneous resolution of the illness in three patients with idiopathic pericarditis, because of neoplastic pericarditis in four (due in three to widespread cancer and in one with mediastinic lymphoma to a good response to pericardiocentesis and chest radiation), and owing to the presence of severe left ventricular function depression in one patient with radiation pericarditis. At the end of the workup, the diagnoses were idiopathic pericarditis in seven patients, neoplastic pericarditis in four, radiation pericarditis in two, postsurgical pericarditis in one, and tuberculous pericarditis in one (Table 2).

#### FOLLOW-UP

Overall follow-up ranged from 1 month to 15 years (median, 7 years). Six patients died between one month and nine years after admission: three with neoplastic pericarditis died as a consequence of the dissemination of the neoplasm, one died of chronic obstructive lung disease, one who had received radiation died of lung fibrosis, and one with lymphoma pericarditis died from brain hemorrhage. One pa-

tient was lost to follow-up. In the six surviving patients (four of whom had undergone pericardiectomy), follow-up ranged from 3 to 15 years (median, 7 years). All were in a good clinical condition, and physical examination revealed no venous hypertension at the last visit in early 2003.

#### DISCUSSION

We have described our experience with effusive-constrictive pericarditis over a period of 16 years. The prevalence of this disorder was only 1.3 percent among patients with pericardial disease of any type (15 of 1184) and 6.9 percent among patients with clinical tamponade (15 of 218). However, the true prevalence is probably higher, since only 190 patients with tamponade underwent catheterization (the prevalence in this subgroup was 7.9 percent). The selection of patients for catheterization was not based on any particular clinical or echocardiographic finding; therefore, it is unlikely that they represent a subgroup with a different prevalence of constriction. Although our hospital is a referral center for

**Table 2. Causes of 1184 Cases of Pericarditis of Any Type from 1986 to 2001 and the Number of Cases of Effusive–Constrictive Pericarditis.**

Cause of Pericarditis	No. of Patients	No. with Effusive–Constrictive Pericarditis
Idiopathic	401	7
Neoplastic	44	4
Postsurgical	125	1
Uremia	85	0
Purulent and tuberculous	55	1
Radiation	7	2
Miscellaneous	467	0

pericardial disease, the prevalence of effusive–constrictive pericarditis may be similar among patients with tamponade who receive care at any tertiary center. The low number of cases may be explained by the relative rarity of this pericardial disorder and by the difficulty of establishing a firm diagnosis.

The medical literature includes case reports of constrictive epicarditis (after exudative pericarditis) that remained clinically unsuspected until autopsy.<sup>1,7,8</sup> The diagnostic accuracy of Doppler echocardiography is probably low, particularly at the time of presentation with tamponade; in fact, in the present series, this technique suggested the presence of concomitant constriction before pericardiocentesis in only 7 of 15 patients. The diagnosis therefore requires the fulfillment of precise hemodynamic criteria during pericardiocentesis with simultaneous cardiac catheterization. Specifically, intrapericardial pressure and right atrial transmural pressure must be measured before and after removal of pericardial fluid (as is the routine practice at our institution). With the use of this approach, as shown in Table 1, before pericardiocentesis, all our patients had right atrial transmural pressure of less than 2 mm Hg or pulsus paradoxus of 10 mm Hg or more — criteria for cardiac tamponade — whereas after pericardiocentesis, only three patients met one of these criteria, and all met morphologic atrial and ventricular pressure criteria for cardiac constriction.

Given the paucity of information in the medical literature, we believe our series contributes importantly to the understanding of this pericardial syndrome. In fact, apart from the original series of Hancock reported more than 30 years ago<sup>3</sup> and the subsequent report by Cameron and colleagues,<sup>4</sup> of 23 cases of effusive–constrictive pericarditis in

a surgical series of 95 patients with constrictive pericarditis who underwent pericardiectomy, only isolated case reports have been published. In Hancock's series of 13 patients, all required wide resection of the parietal and visceral layers of the pericardium. The cause of pericardial disease was idiopathic in nine patients and related to radiotherapy in four. Although detailed description of the clinical characteristics is provided, information on the characteristics of the population from which the patients were selected is lacking, and as previously mentioned, all patients underwent pericardiectomy. Therefore, the place occupied by effusive–constrictive pericarditis in the entire group of patients with pericardial disease and the pattern of evolution of this condition with the use of a more conservative approach cannot be ascertained from those data.

In our series, the etiologic spectrum of effusive–constrictive pericarditis was similar to that in the series reported by Hancock,<sup>3</sup> with a predominance of idiopathic cases, together with cases that occurred after radiotherapy or cardiac surgery or as a result of neoplasia or tuberculosis. The cause of the 1184 cases of pericarditis seen at our institution during the same period (Table 2) provides some idea of the proportion of patients in each group in whom tamponade with effusive–constrictive characteristics develops. In the literature, cases of effusive–constrictive pericarditis of idiopathic origin<sup>3,9</sup> or due to chest radiation,<sup>3</sup> chemotherapy,<sup>10</sup> or various infectious agents<sup>11–16</sup> have been reported. Thus, effusive–constrictive pericarditis can occur in all types of pericarditis with effusion but is relatively more frequent in radiation-related pericarditis and relatively less frequent in postsurgical cases. In fact, this etiologic spectrum reflects, to a certain extent, the general etiologic spectrum of pericardial diseases in each area and can be influenced by the changing etiologic spectrum of pericarditis in general and constrictive pericarditis in particular.<sup>4,17</sup> It is likely that the etiologic spectrum would be different in series from other parts of the world or at institutions that specialize in the treatment of specific types of disease (such as cancer centers or cardiac surgery centers).

The importance of recognizing the hemodynamic syndrome of tamponade and constriction characteristic of effusive–constrictive pericarditis lies in an acknowledgment of the contribution of the visceral layer of the pericardium to the pathogenesis of constriction and of the need to remove it surgi-

cally. However, in our series, in contrast to that of Hancock, pericardiectomy was not performed in 8 of 15 patients: in 5 of them owing to a poor general prognosis (4 patients with neoplastic pericarditis) or a high surgical risk (1 patient with radiation pericarditis) and in 3 patients (all with idiopathic pericarditis) because of progressive improvement and, eventually, resolution of the illness after pericardiocentesis. Remarkably, in two of these three patients with resolution, the onset of symptoms was very recent. The finding that tamponade and constriction resolved in some patients after pericardiocentesis, without the need for pericardiectomy, concurs with our previous observation of the spontaneous resolution in some cases of constrictive

pericarditis that developed during the resolution of idiopathic acute exudative pericarditis — so-called transient cardiac constriction.<sup>18</sup> Other authors have made similar observations.<sup>10,19</sup> Accordingly, and particularly in cases of idiopathic origin, pericardiectomy should be delayed unless constriction becomes severe and persistent.

In summary, effusive-constrictive pericarditis is an uncommon pericardial syndrome that may be missed in some patients presenting with tamponade. The causes are diverse, and its course may be reversible. In patients requiring surgery, particular attention should be paid to the extent of the involvement of visceral pericardium should extensive epicardiectomy be necessary.

## REFERENCES

- Burchell HB. Problems in the recognition and treatment of pericarditis. *J Lancet* 1954; 74:465-70.
- Spodick DH, Kumar S. Subacute constrictive pericarditis with cardiac tamponade. *Dis Chest* 1968;54:62-6.
- Hancock EW. Subacute effusive-constrictive pericarditis. *Circulation* 1971;43: 183-92.
- Cameron J, Oesterle SN, Baldwin JC, Hancock EW. The etiologic spectrum of constrictive pericarditis. *Am Heart J* 1987;113: 354-60.
- Permanyer-Miralda G, Sagristà-Sauleda J, Soler-Soler J. Primary acute pericardial disease: a prospective series of 231 consecutive patients. *Am J Cardiol* 1985;56:623-30.
- Service of Cardiology, Hospital General Vall D'Hebron. Protocol for the diagnosis and management of pericardial diseases. In: Soler-Soler J, Permanyer-Miralda G, Sagristà-Sauleda J, eds. *Pericardial disease: new insights and old dilemmas*. Vol. 108 of *Developments in cardiovascular medicine*. Dordrecht, the Netherlands: Kluwer Academic, 1990:217-22.
- Fowler N, Bove KE, Dunbar S, Meyer R. Fatigue, dyspnea, and abdominal swelling in a 13-year-old boy. *Am Heart J* 1978;96: 533-42.
- Walsh TJ, Baughman KL, Gardner TJ, Bulkley BH. Constrictive epicarditis as a cause of delayed or absent response to pericardiectomy: a clinicopathological study. *J Thorac Cardiovasc Surg* 1982;83:126-32.
- Tsang TS, Barnes ME, Gersh BJ, Bailey KR, Seward JB. Outcomes of clinically significant idiopathic pericardial effusion requiring intervention. *Am J Cardiol* 2003;91: 704-7.
- Woods T, Vidarsson B, Mosher D, Stein JH. Transient effusive-constrictive pericarditis due to chemotherapy. *Clin Cardiol* 1999; 22:316-8.
- Doig JC, Hilton CJ, Reid DS. Salmonella: a rare cause of subacute effusive-constrictive pericarditis. *Br Heart J* 1991;65:296-7.
- Hirata K, Asato H, Maeshiro M. A case of effusive constrictive pericarditis caused by *Streptococcus milleri*. *Jpn Circ J* 1991;55:154-8.
- Oudiz R, Mahaisavariya P, Peng SK, et al. Disseminated coccidioidomycosis with rapid progression to effusive-constrictive pericarditis. *J Am Soc Echocardiogr* 1995;8:947-52.
- D'Cruz IA, Pallas CW, Heck A. Echocardiographic diagnosis of effusive-constrictive pericarditis due to staphylococcal pericarditis after cardiac surgery. *South Med J* 1991; 84:1375-7.
- Hugo-Hamman CT, Scher H, De Moor MM. Tuberculous pericarditis in children: a review of 44 cases. *Pediatr Infect Dis J* 1994; 13:13-8.
- Satoh T, Kojima M, Ohshima K. Demonstration of the Epstein-Barr genome by the polymerase chain reaction and in situ hybridisation in a patient with viral pericarditis. *Br Heart J* 1993;69:563-4.
- Ling LH, Oh JK, Schaff HV, et al. Constrictive pericarditis in the modern era: evolving clinical spectrum and impact on outcome after pericardiectomy. *Circulation* 1999;100: 1380-6.
- Sagristà-Sauleda J, Permanyer-Miralda G, Candell-Riera J, Angel J, Soler-Soler J. Transient cardiac constriction: an unrecognized pattern of evolution in effusive acute idiopathic pericarditis. *Am J Cardiol* 1987; 59:961-6.
- Tanaka K, Kawauchi M, Murota Y, et al. Reversible subacute effusive-constrictive pericarditis after correction of double-chambered right ventricle: a case report. *J Cardiol* 2002; 39:267-70.

Copyright © 2004 Massachusetts Medical Society.